

Original Article

Fracture in the Neck of Femur in Adult Patients and Treatment Outcome of DHS With De-rotation Screw Method: A Cross Sectional Study in a Tertiary Care Hospital, Bangladesh

Saha SK,¹ Akhiruzzaman,² Nazibullah M,³ Islam MT,⁴ Paul S,⁵ Bari R⁶

Abstract

Background: Femoral neck fracture is a challenging orthopedic injury and internal fixation is the best treatment option for young and middle-aged adults where joint preservation is crucial. Dynamic Hip Screw (DHS) fixation with an additional de-rotation screw has been introduced to improve rotational stability and enhance union rates, yet limited evidence exists in Bangladesh. **Objective:** To evaluate the fracture patterns, complications, radiological union and functional outcomes of adult patients with femoral neck fractures treated with DHS and de-rotation screw fixation in a tertiary care hospital in Bangladesh. **Methods:** This descriptive cross-sectional study was carried out in the Department of Orthopedic Surgery at Chattogram Medical College Hospital, over 18 months. A total of 60 adult patients (≥ 18 years) with unilateral femoral neck fractures treated with DHS and de-rotation screw fixation were included. Patients with pathological fractures, multiple injuries or prior hip surgery were excluded. All underwent standard DHS with de-rotation screw fixation under spinal anesthesia. Patients were followed up at 3rd, 6th, 9th, and 12th month. Outcomes were assessed using radiological union criteria and the Harris Hip Score (HHS). Data were analyzed by using SPSS (version 25). Ethical issues were maintained strictly at every stage of the study. **Results:** The mean (\pm SD) age of the patients was 34.7 (± 11.3) years, with a male predominance (83.3%). Road traffic accidents were the leading cause of injury (66.7%) and basicervical fractures (B-3 type) were most common (63.3%). Non-union and hip stiffness were the most frequent complications (10.0%). By 12 months, 95.9% of patients were pain-free, 93.9% walked without a limp, and 98% achieved unaided mobility. All patients attained unlimited walking distance and full sitting comfort by final follow-up. Weight-bearing milestones improved progressively, with 64.3% bearing full weight at 6 weeks, 88.9% at 9 weeks, and 100% at 12 weeks. At one year, functional outcomes were excellent in 69.4%, good in 24.5%, and fair in 6.1%, with no poor outcomes. **Conclusion:** DHS with de-rotation screw fixation is an effective and reliable treatment for femoral neck fractures in young and middle-aged adults. It provides high union rates, favorable functional recovery and acceptable complication rates. Despite longer operative times this method offers best bio-mechanical stability and should be considered a preferred option in resource-limited settings such as Bangladesh.

Keywords: Femoral neck fracture, Dynamic Hip Screw, de-rotation screw, Harris Hip Score, internal fixation, Bangladesh.

Received on: 19.12.25; Revised on: 01.04.26; Accepted on: 15.04.26

Introduction:

Femoral neck fracture (FNF) is one of the common and challenging injuries in orthopedic trauma due to their unique intra-capsular location, high blood supply, and more risk of complications such as non-

union and avascular necrosis (AVN).¹ They represent approximately 3.6% of all fractures and 50–60% of all hip fractures worldwide, making them a significant public health problem.^{2,3} In the global population, the

Author's Affiliation:

1. *Shantonu Kumar Saha, Assistant Professor, Department of Orthopedics, TMSS Medical College and Rafatullah Community Hospital, Bogura.
2. Akhiruzzaman, Associate Professor and Head, Department of Community Medicine and Public Health, TMSS Medical College, Bogura.
3. Md. Nazibullah, Associate Professor and Unit Head, Department of Orthopedics, TMSS Medical College and Rafatullah Community Hospital, Bogura.
4. Md. Tariqul Islam, Associate Professor, Department of Orthopedics, TMSS Medical College and Rafatullah Community Hospital, Bogura.
5. Susmita Paul, Diploma in Child Health (DCH) Fellow, TMSS Medical College and Rafatullah Community Hospital, Bogura.
6. Rohmatul Bari, Resident Surgeon, Department of Orthopedics, TMSS Medical College and Rafatullah Community Hospital, Bogura.

Address of Correspondence : *Dr. Shantonu Kumar Saha, Assistant Professor, Department of Orthopedics, TMSS Medical College and Rafatullah Community Hospital, Bogura. Mobile: +8801774299657

E-mail: drshantonu1saha@gmail.com

burden of femoral neck fractures is expected to rise dramatically with projection of estimating over 6.3 million hip fractures annually by 2050.⁴

The epidemiology of these fractures varies between developed and developing nations. Among the high-income countries, femoral neck fractures predominantly occur in elderly women due to osteoporosis and falls.⁵ In contrast, in low- and middle-income countries (LMICs) such as Bangladesh, a substantial proportion of cases occur in younger adults, often as a result of high-energy trauma including road traffic accidents and falls from height.⁶ This demographic differences create unique management challenges because younger patients require preservation of the femoral head to maintain mobility, activity, and quality of life.¹

The goals of treatment for femoral neck fractures are to achieve anatomical reduction, provide stable fixation, preserve vascularity of the femoral head and allow early mobilization.⁷ A variety of surgical techniques have been developed, broadly categorized into internal fixation and arthroplasty. While arthroplasty is often preferred in elderly patients with displaced fractures, internal fixation remains the mainstay in young and middle-aged adults, where preservation of the joint is essential.⁸

Among internal fixation methods, the Dynamic Hip Screw (DHS) has been widely used since the 1960s and remains one of the most reliable implants for femoral neck fracture fixation.⁹ The DHS consists of a large lag screw connected to a side plate, allowing controlled sliding and compression at the fracture site. Though DHS provides bio-mechanical stability but concerns exist about rotational instability of the femoral head which may lead to fixation failure. To overcome this condition, the addition of a de-rotation screw has been proposed. The de-rotation screw improves rotational stability, reduces shear forces and enhances the likelihood of union.¹⁰

Recent studies have shown that DHS with de-rotation screw fixation achieves higher union rates and better functional outcomes compared to other methods.^{11,12} A systematic review found that DHS constructs with additional anti-rotation screws resulted in significantly lower fixation failure rates and reduced femoral neck shortening.¹ Similarly, clinical trials in South Asia have demonstrated favorable results with DHS fixation in terms of union and Harris Hip Score outcomes.^{13,14}

In Bangladesh, femoral neck fractures constitute a considerable proportion of orthopedic admissions. A hospital-based study from Dhaka showed that the majority of affected patients were young males and road traffic accidents were the leading cause of injury.¹⁵ Despite the frequent use of DHS in tertiary hospitals the long-term outcomes remains limited in the Bangladeshi context.

Given the burden of femoral neck fractures in young and middle-aged adults and the potential benefits of DHS with de-rotation screw fixation, it is crucial to generate local evidence to guide clinical decision-making. So, this study aimed to evaluate the demographic profile, clinical outcomes and functional results of patients with femoral neck fractures treated with DHS and de-rotation screw fixation in a tertiary care hospital in Bangladesh.

Methodology

This descriptive cross-sectional study was conducted for the period of 18 months at the Department of Orthopedic Surgery, Chattogram Medical College Hospital (CMCH), which is a tertiary care hospital in Bangladesh. A total of 60 adult patients with femoral neck fractures were purposively selected and prospectively observed during the study period, who were treated with DHS and de-rotation screw fixation method. Age more equal 18 years irrespective of sex who had unilateral femoral neck fracture and medically fit for anesthesia and surgery were included in this study. Had pathological fractures (other than osteoporosis), Patients with multiple injuries or poly trauma, Previous hip surgery or failed internal fixation and unwilling or unable to provide informed consent were excluded. Each patient underwent a complete clinical assessment, including demographic details, mechanism of injury and comorbid conditions. Preoperative investigations (CBC, electrolytes, ECG, chest X-ray, and anesthetic evaluation) were performed accordingly.

Procedure of Surgery (DHS with de-rotation screw method):

1. After administering spinal anaesthesia, the patient was positioned supine on a fracture table with a perineal post. The injured limb was placed in a boot and the contralateral lower extremity was placed in a well-leg holder.
2. The fluoroscope was placed in between the legs in all cases to obtain good quality images in all planes.
3. Provisional reduction was done with the Whitman, lead better, smith Peterson or others reduction technique. Additional adjustments were made if necessary by increasing or decreasing traction or altering abduction/adduction and internal/external rotation. Care was taken to avoid common malalignments.
4. The limb was prepped with 10% povidone iodine from the iliac crest up to the knee and draped with sterile sheets in standard fashion.
5. Proximal femur was approached from the lateral side and an incision was given from the tip of the trochanter to 8-10cm distal. Dissection was carried through the deep fascia and the fascia of the vastus lateralis was incised longitudinally.

6. The vastus lateralis was elevated anteriorly off the lateral intermuscular septum.
 7. Cut vessels were coagulated as they were encountered.
 8. A guide wire was inserted with the help of an angle guide from mid-lateral cortex about 2cm distal to the flare of the greater trochanter. This roughly corresponded with opposite site of the lesser trochanter on fluoroscopy. The guide wire was inserted in a centre-centre position and the tip was advanced to within 5mm subchondral bone. The length of the inserted part of the guide wire was measured. Another guide wire was inserted just above to the distal guide wire for de-rotation screw.
 9. The triple reamer was set 5mm shorter from the length of the measurement of the guide wire and bone was reamed over the guide wire. Care was taken not to advance the guide wire into the pelvis when reaming.
 10. A tap was used to tap the reamed canal.
 11. A lag screw was chosen same length as the triple reamer and inserted with the help of insertion wrench.
 12. An appropriate length of plate was inserted and was carefully seated to the bone and fixed with 4.5mm cortical screws engaging both cortex. Finally derotation screw was inserted over the upper guide wire.
 13. Two guide wire were removed and compression screw was inserted in the lag screw. Traction was removed and compression applied with the lag screw. Reduction and stability was checked.
 14. Hemostasis was ensured. The vastus lateralis fascia was closed with 1/0 absorbable interrupted sutures and the deep fascia was closed with 1/0 absorbable suture in continuous fashion over a drain. Subcutaneous sutures were applied with 2/0 absorbable sutures in interrupted fashion. Finally, skin was closed with skin staplers and sterile dressing was applied.
 15. Patient was removed from the fracture table and sent to the post-operative recovery unit.
- Drain was removed after 48 hours and stitches were removed after 14 days in all patients.
 - ROM exercise of hip and knee and muscle strengthening exercise of the quadriceps and hamstrings and hip abductors and hip extensors were initiated after cessation of post-operative pain.
 - All patients were mobilized in axillary crutches or walker if unable to mobilize in axillary crutches.
 - Toe touch weight bearing was allowed after cessation of post-operative pain. Partial weight bearing was allowed at 4-6 weeks according to the follow-up radiographs and full weight bearing was allowed at 10-12 weeks given that the patient was able to fully bear weight without any pain indicating union.
 - Patients were scheduled for follow-up at 3rd, 6th, 9th and 12th month. Functional assessment was done by using Harris Hip Score (1969).
 - Patients who developed deep infection was admitted and wound debridement done under spinal anaesthesia. Pus for C/S was sent and further treated accordingly.

Follow-up:

Patients were followed up at 3rd, 6th, 9th and 12th month. At each visit, clinical and radiological evaluations were performed. Radiological outcome was assessed by union of bone which was defined as bridging trabeculae and disappearance of fracture line on at least three cortices. Clinical and functional outcomes were measured by pain, limp, support, distance walked, sitting, enter public transportation, climbing stairs, put on socks and shoes, absence of deformity and range of motion were assessed. Complications were assessed by non-union, delayed union, implant failure, avascular necrosis (AVN). Harris Hip Score (HHS, 1969) was used for assessing the functional outcome and scored as Excellent: 90–100; Good: 80–89; Fair: 70–79; Poor: <70

Data were collected using a structured case record form. Continuous variables (age, operative time, HHS) were presented as mean \pm SD. Categorical data (sex, complications, outcomes) were summarized as frequencies and percentages. Statistical analysis was carried out using SPSS (version 25.0). Ethical approval was obtained from the Institutional Review Board (IRB) of Chattogram Medical College. Written informed consent was obtained from all participants after explaining the study objectives, surgical procedure, and potential risks and benefits. Confidentiality and anonymity were maintained strictly.

Post-operative Management:

- All patients received I/V cefuroxime 750mg 8 hourly and I/V flucloxacillin 500mg 6 hourly up to the 4th POD. Then they were switched to oral antibiotics for further 10 days.

Results

Table-1: Distribution of the respondents according to their socio-demographic characteristics (n=60)

Variable	Category	Frequency (%)
Age (years)	18-25	14(23.33)
	26-35	22(36.66)
	36-45	12(20.00)
	46-55	12(20.00)
	Mean(±SD)	34.7 (±11.3)
Sex	Male	50(83.33%)
	Female	10(16.67%)
Occupation	Service holders	18(30.00%)
	Laborers	16(26.67%)
	Students	12(20.00%)
	Others	14(23.33%)
Monthly income (BDT)	<10,000	18(30.00%)
	10,000–20,000	32(53.33%)
	>20,000	10(16.67%)

Table-1 shows the socio-demographic distribution of patients. The mean (±SD) age was 34.7(±11.3) years, with the highest proportion (36.7%) in the 26–35-year age group. Males predominated (83.3%), giving a male-to-female ratio of about 5:1. Service holders (30.0%) and laborers (26.7%) were the most common occupations, followed by students (20.0%). More than half of the respondents (53.3%) had a monthly income between 10,000–20,000 BDT, while 30.0% had an income below 10,000 BDT.

Table-2: Distribution of the respondents regarding information related to injury (n=60)

Attributes	Category	Frequency (%)
Mechanism of injury	Road Traffic Accident	40 (66.7%)
	Fall	20 (33.3%)
Side of fracture	Right	28 (46.7%)
	Left	32 (53.3%)
Fracture type (AO/OTA)	B1	4 (6.7%)
	B2	18 (30.0%)
	B3	38 (63.3%)

Table 2 demonstrates that road traffic accidents were the leading mechanism of injury, accounting for 66.7% of cases, while 33.3% sustained fractures due to falls. The left side was slightly more affected (53.3%) compared to the right (46.7%). Regarding fracture type (AO/OTA classification), basicervical fractures (B3) were most frequent (63.3%), followed by transcervical (B2, 30.0%) and subcapital (B1, 6.7%).

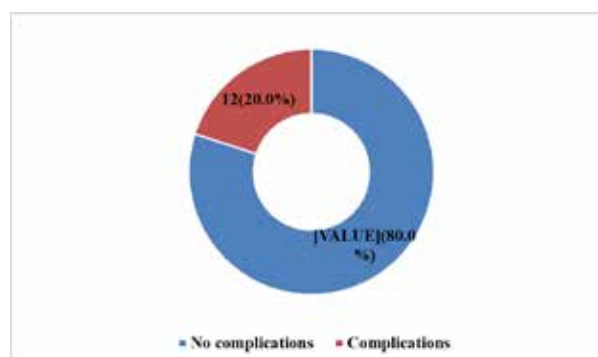


Figure-1: Distribution of the respondents according to post-operative complications (n=60)

Figure-1 shows that only 12(20%) of the respondents developed post-operative complications and 80% had no complications

Table-3: Distribution of the respondents regarding information related to post-operative complications

Complication	Frequency n=12*	Percentage	Valid Percentage (n=60)
Superficial infection	4	33.33	6.66
Deep infection	2	16.66	3.33
Delayed union	2	16.66	3.33
Non-union	6	50.0	10.0
Hip stiffness	6	50.0	10.0
Avascular necrosis	4	33.33	6.66
* Multiple answers			

Table-3 illustrates the postoperative complications. Non-union and hip stiffness were the most common, which was 50.0% among all the complication. Avascular necrosis and superficial wound infection were 33.33%. Deep infection (16.66%) and delayed union 16.66% were less frequent. Overall, nearly one-fifth of the patients experienced some form of complication.

Table-4(a): Distribution of the respondents according to functional outcome in different visits

Attributes	3 months (n=60)	6 months (n=56)	9 months (n=54)	12 months (n=49)
Pain				
Marked	0(0.0%)	0(0.0%)	0(0.0%)	0(0.0%)
Moderate	12(20%)	2(3.57%)	0(0.0%)	0(0.0%)
Mild	22(36.67%)	16(28.56%)	0(0.0%)	0(0.0%)
Slight	22(36.67%)	20(35.71%)	8(14.81%)	2(4.08%)
None	4(6.67)	18(32.14%)	46(85.19%)	47(95.92%)
Limp				
Severe	2(3.33%)	0(0.0%)	0(0.0%)	0(0.0%)
Moderate	24(40.0%)	2(3.57%)	0(0.0%)	0(0.0%)
Slight	34(56.67%)	32(57.14%)	4(7.41%)	3(6.12%)
None	0(0.0%)	22(39.28%)	50(92.59%)	46(93.87%)
Support				
Two canes	6(10%)	0(0.0%)	0(0.0%)	0(0.0%)
One crutch	44(73.33%)	4(7.14%)	1(1.87%)	0(0.0%)
Cane most of the time	4(6.67%)	2(3.57%)	2(3.70%)	0(0.0%)
Cane for long walks	4(6.67%)	24(42.85%)	3(5.55%)	1(2.04%)
None	2(3.33%)	26(46.42%)	48(88.88%)	48(97.96%)
Distance walked				
Two or three blocks	06(10.0%)	0(0.0%)	0(0.0%)	0(0.0%)
Six blocks	14(23.33%)	6(6.71%)	6(11.11%)	5(10.20%)
Unlimited	40(66.67%)	50(89.29%)	48(88.89%)	44(89.80%)
Sitting				
Unable to sit comfortably	2(3.33%)	0(0.0%)	0(0.0%)	0(0.0%)
On a high chair for 30 minutes	18(30.0%)	4(7.14%)	6(11.11%)	3(6.12%)
Comfortably for 1 hour	40(66.67%)	52(92.85%)	48(88.89%)	46(93.88%)

Table-4(b): Distribution of the respondents according to functional outcome in different visits

Attributes	3 months (n=60)	6 months (n=56)	9 months (n=54)	12 months (n=49)
Enter public transportation				
No	2(3.33%)	2(3.57%)	2(3.70%)	0(0.0%)
Yes	58(96.67%)	54(96.43%)	52(96.30%)	49(100%)
Climbing stairs				
Unable	2(3.33%)	0(0.0%)	0(0.0%)	0(0.0%)
In any manner	4(6.67%)	0(0.0%)	0(0.0%)	0(0.0%)
Using a railing	50(83.33%)	4(7.14%)	4(7.41%)	3(6.12%)
Without railing	4(6.67%)	52(92.85%)	50(92.59%)	46(93.87%)
Put on Socks and Shoes				
Unable	06(10.0%)	0(0.0%)	0(0.0%)	0(0.0%)
With difficulty	50(83.33%)	4(7.14%)	6(11.11%)	3(6.12%)
With ease	4(6.67%)	52(92.85%)	48(88.89%)	46(93.87%)
Absence of deformity				
No	06(10.0%)	4(7.14%)	6(11.11%)	3(6.12%)
Yes	54(90.0%)	52(92.85%)	48(88.89%)	46(93.87%)
Range of motion				
31°-60°	2(3.33%)	0(0.0%)	0(0.0%)	0(0.0%)
61°-100°	12(20.0%)	4(7.14%)	0(0.0%)	0(0.0%)
101°-160°	42(70.0%)	6(6.71%)	4(7.41%)	0(0.0%)
161°-210°	4(6.67%)	46(82.14%)	8(14.81%)	5(10.20%)
211°-300°	0(0.0%)	0(0.0%)	42(77.78%)	44(89.80%)

Table 4(a) presents functional outcomes across follow-up visits using Harris Hip Score parameters. At three months, many patients reported mild to slight pain, but by 12 months, almost all (95.92%) were pain-free. Limping improved significantly over time, with 93.87% walking without a limp at 12 months. Use of walking support reduced progressively, and by 12 months, nearly all patients (97.96%) walked unaided. Walking distance also improved, with all patients able to walk unlimited distances by 12 months. Sitting tolerance increased, and by 12 months, all patients could sit comfortably for one hour.

Table 4(b) shows other functional parameters. The ability to use public transportation improved, with all patients achieving this by 12 months. Similarly, stair climbing ability progressed and by 12 months, 93.87% could climb without using a railing, while the remainder managed with a railing. Almost all patients could put on socks and shoes with ease (93.87%) by 12 months. Deformity was absent in most patients by the final follow-up (93.87%). Range of motion improved steadily, with the majority (89.80%) reaching >210° by 12 months.

Table-5: Distribution of the responded by time required for bearing full weight

Attributes	n	Bear full weight		Could not bear full weight	
		Frequency	Percentage	Frequency	Percentage
During 6 th weeks	56	36	64.28	20	35.72
During 9 th weeks	54	48	88.88	06	11.12
During 12 th weeks	49	49	100.00	00	00

Table 5 highlights weight-bearing milestones. By the 6th week, 64.28% of patients could bear full weight, while the remainder required more time. At 9 weeks, 88.8% were fully weight-bearing, and by the 12th week, all patients (100%) achieved full weight-bearing without support.

energy trauma such as road traffic injuries and falls from height.^{6,16} In contrast, data from developed nations show that femoral neck fractures are more common in elderly women, largely due to osteoporosis and low-energy falls.⁵ A hospital-based study in Bangladesh similarly reported that the majority of patients were young men injured in road traffic accidents.¹⁵

Table-6: Functional outcome score at 12th months according to Harris Hip Score (n=49)

Harris Hip Score	Frequency	Percentage
Excellent (Score: 90–100)	34	69.39
Good (Score: 80–89)	12	24.49
Fair (Score: 70–79)	3	6.12
Poor (Score: <70)	0	00

In this study, 90% of fractures united within an average of 17.1 weeks, with non-union occurring in 10%. These results are comparable with previous literature, where DHS fixation has reported union rates between 85% and 92%.^{8,10} The addition of a derotation screw enhances rotational stability and decreases the risk of fixation failure, which may explain the favorable outcomes in our series. In contrast, non-union rates after cannulated screw fixation are generally higher, ranging from 15–25% in displaced fractures.^{11,12}

Table-6 shows that most (69.39%) of the respondents' functional outcome score was 90 to 100 (Excellent) and 24.49% had good score and no poor score was found during visit

Complication rates in this study were relatively low, with AVN observed in 6.6% of patients. This is slightly lower than the 10–20% AVN rates reported in recent reviews.^{1,7} AVN is strongly linked to the initial injury rather than fixation method, as disruption of the femoral head blood supply occurs at the time of fracture.¹ Other complications in our series included hip stiffness (10%), wound infections (10%), and delayed union (3.3%). These rates are consistent with similar regional studies.¹⁴

Discussion:

This study evaluated the outcomes of femoral neck fractures in adults treated with Dynamic Hip Screw (DHS) with de-rotation screw fixation method in a tertiary care hospital. The results showed a union rate of 90%, with 69.39% of patients achieving excellent and 24.49% had good functional outcomes at 12 months. These findings highlight DHS with de-rotation screw as a reliable fixation method for femoral neck fractures in young and middle-aged adults.

At one year (last follow-up) 83.3% of patients achieved excellent to good results on the Harris Hip Score. This is in line with studies showing that DHS with de-rotation screw fixation provides better functional stability compared to cannulated screws, particularly in displaced fractures.¹³ Sidhu et al. (2012) also demonstrated superior rotational stability and functional recovery when a de-rotation screw was added to DHS.¹⁰

Most of the patients were young males (83.33%), with a mean (±SD) age of 34.7(±11.3) years, and road traffic accidents were the predominant cause of fracture (66.7%). This is consistent with previous reports from South Asia, where younger populations sustain high-

The Femoral Neck System (FNS) has emerged as a newer alternative to both DHS and CHS. Systematic reviews suggest that FNS reduces femoral neck shortening and fixation failure compared with CHS, though outcomes compared with DHS remain comparable.¹² However, in low-resource countries such as Bangladesh, the high cost and limited availability of FNS restrict its use. DHS with derotation screw therefore remains a practical and effective option in this context.

Conclusion

DHS with derotation screw fixation is an effective surgical option for treating femoral neck fractures in adults, particularly in young patients with high-energy trauma. It provides excellent mechanical stability, high union rates, and favorable functional outcomes, despite requiring longer operative time and greater blood loss compared to other techniques. This method should be considered a reliable fixation strategy in tertiary care centers in Bangladesh, especially where joint-preserving surgery is prioritized over arthroplasty.

References:

1. Ly, T.V., Swart, E., Wei, D.T., George, J. & Slobogean, G.P. Advances in management of femoral neck fractures in young adults. *Bone & Joint Journal*, 2023, 105-B(5), pp.524–533.
2. Court-Brown, C. M., & Caesar, B. Epidemiology of adult fractures: A review. *Injury*, 2006, 37(8), 691–697.
3. Broderick, J. M., et al. Epidemiology of femoral neck fractures. *Clinical Orthopaedics and Related Research*, 2013, 471(8), 2462–2469.
4. Dhanwal, D. K., et al. Epidemiology of hip fracture: Worldwide geographic variation. *Indian Journal of Orthopaedics*, 2011, 45(1), 15–22.
5. Shoda, E., Matsubara, M., Kida, Y., Ito, A. and Nishino, M. Epidemiology and outcomes of femoral neck fractures in elderly women: A 10-year observational study. *Journal of Orthopaedic Science*, 2020, 25(5), pp.756–763.
6. Yoon, B.H., Cho, J.W., Yoo, J.J., Yoon, K.S. & Kim, H.J. Internal fixation of femoral neck fractures in young adults: a multicenter retrospective study of 260 cases. *Journal of Orthopaedic Trauma*, 2020, 34(4), pp.194–200.
7. Ye, Y., Chen, K., Tian, K., Zhu, Q. and Zhang, K. Surgical management of femoral neck fractures in young adults: A review. *Orthopaedic Surgery*, 2020, 12(3), pp.986–995.
8. Gupta, R., Gupta, A.K., Gupta, S.K. and Mittal, A. Outcome of internal fixation of femoral neck fractures in young adults. *Injury*, 2016, 47(S3), pp.S65–S73.
9. Leighton, R.K. Fractures of the neck of the femur. In: Bucholz, R.W. and Heckman, J.D., eds. *Rockwood and Green's fractures in adults*. 6th ed. Philadelphia: Lippincott Williams & Wilkins, 2006, pp.1753–1791.
10. Sidhu, S., Arora, A. and Gill, S.S. Rotational stability of femoral neck fractures treated with dynamic hip screw and derotation screw. *Indian Journal of Orthopaedics*, 2012, 46(2), pp.115–121.
11. Kaplan, T., Sahin, V., Bilge, O., Ozden, V.E. and Poyanli, O. Comparison of dynamic hip screw and cannulated screw fixation for the treatment of femoral neck fractures. *Acta Orthopaedica Belgica*, 2012, 78(4), pp.432–438.
12. Wang, Z., Li, Z., Zhang, X., Wang, H., Wu, H. and Jiang, W. Femoral Neck System versus cannulated screws for femoral neck fractures: A systematic review and meta-analysis. *World Journal of Clinical Cases*, 2022, 10(31), pp.11454–11465.
13. Parvez, A., Rahman, M.M., Karim, M.M. and Sultana, N. Comparison between DHS with derotation screw and cannulated screw fixation in femoral neck fractures. *Journal of Chittagong Medical College Teachers' Association*, 2018, 29(1), pp.12–18.
14. Rahman, M.M., Sarker, R., Hossain, M.A. & Sultana, S. Functional outcomes of cannulated hip screw fixation in intracapsular femoral neck fractures. *TAJ: Journal of Teachers Association*, 2021, 34(2), pp.31–38.
15. Hossain, M., Rahman, M.A., Karim, M.R. and Hasan, M.S. Patterns of femoral neck fractures in Bangladesh: A hospital-based study. *Bangladesh Journal of Orthopaedics*, 2019, 34(1), pp.22–28.
16. Shah, A. K., Eissler, J., & Radomisli, T. Femoral neck fractures in young adults. *Journal of the American Academy of Orthopaedic Surgeons*, 2002, 10(6), 345–354